



# Effect of COVID 19 vaccination on the CT severity score for SARS CoV2 pneumonia- an experience from the initial wave

Batra<sup>a</sup>, R.; Harish C<sup>a</sup>, S.; Gupta<sup>a</sup>, S.; Garg<sup>a</sup>, A

<sup>a</sup> Department of Radiodiagnosis, Maulana Azad Medical College & LNJP Hospital,  
New Delhi, India, Pin code- 110002.

snehaharishc@gmail.com

---

## ABSTRACT

The severe acute respiratory syndrome coronavirus 2 pandemic started in the December of 2019 at China. The second wave of the pandemic in India peaked between April-May 2021. In order to reduce the transmission and infectivity of the virus several vaccines were approved for emergent use. Studies have shown the effectiveness of vaccination in reducing the clinical severity of infection by the corona virus. In this study we aim to assess the effect of vaccination on the computed tomography severity score (CTSS). The study included 140 patients who tested positive for COVID 19 on RT PCR or rapid antigen test. Seventy of these patients had received at least one dose of vaccination and 70 patients were unvaccinated. CT scan of the chest was done for all patients and a CTSS ranging from 0 to 25 was assigned depending on the extent of lobar involvement. We found that a higher percentage (72.86%) of unvaccinated patients had severe disease compared to the vaccinated group (38.57%), 5.71% of unvaccinated patients had mild disease compared to 30% of vaccinated patients. The difference between the two groups was found to be statistically significant. On comparing the CTSS of patients with and without vaccination in our study, we found a significant reduction in the severity scores in the vaccinated group. Through this study the vaccine's efficacy could be validated objectively. This article aims to emphasize the role of vaccination in our fight against the pandemic caused by the corona virus.

**Keywords:** COVID-19, vaccination, CTSS.

---



## 1. INTRODUCTION

The pandemic caused by the highly infectious severe acute respiratory syndrome coronavirus 2 (SARS-CoV-2) started in the December of 2019 in Wuhan, China. Several new mutants have emerged across the globe having increased transmissibility and infectivity. The number of cases confirmed worldwide now exceed 621 million and over 6.5 million deaths have been reported globally [1]. In what was known as the largest vaccination drive in the world, India pledged to vaccinate millions of frontline workers during the first phase which was then extended to the entire adult population of the country. The most widely used vaccines that were approved for use in India included Covishield (ChAdOx1 nCoV-19) (by Serum Institute of India Ltd.) and Covaxin (BBV152) (by Bharat Biotech International Ltd.). Covishield is an adenovirus vector-based vaccine whereas Covaxin is an inactivated virus vaccine using imidazoquinoline as an adjuvant to boost immune response and to provide longer-lasting immunity. Sputnik-V (Gam-COVID-Vac), the Russian two vector vaccine also based on adenoviruses, was the third vaccine approved for emergency use in India. Apart from those approved for use, several other vaccines are also under trial in India [2]. Vaccines are however not 100 per cent effective in preventing illness. Detection of SARS-CoV-2 RNA or antigen in a respiratory specimen collected from a person 14 days after receiving the recommended doses of vaccine is defined as breakthrough infection [3].

The most common imaging finding seen in COVID-19 pneumonia is the presence of multifocal ground glass opacities in bilateral lungs showing posterior and basal predominance. In this study our aim was to assess the effect of vaccination on the CT severity score. The CT severity score has been designed to assess the severity of COVID 19 pneumonia, in patients infected by the SARS-CoV-2 virus. Studies have shown that the use of vaccination reduces the clinical severity of infection by the corona virus even though it might not prevent infection by the virus [4,5]. This has been reflected in the CT severity score of the vaccinated patients in our study.

## 2. MATERIALS AND METHODS

A cross-sectional study was conducted in our institution between the months of March 2021 and June 2021 after obtaining clearance from the institutional ethical committee

(F.1/IEC/MAMC/91/03/2022/No 402, dated 29/09/2022). Consent was not required as there was no interaction with the study subjects and all the data was obtained from the departmental database. Anonymity of the subjects has been preserved throughout the manuscript. The study also conforms to the provisions of the Declaration of Helsinki (as revised in 2013). The study included 140 patients positive for COVID-19 (either on RTPCR or rapid antigen test) who were referred to the department of Radiology for CT scan of the chest. Fifty-nine patients had co-morbidities in the form of diabetes and hypertension. Of these patients, 70 had received at least one dose of vaccination and 70 patients were unvaccinated. Twenty-three of these patients had received Covaxin and 47 had received Covishield. Out of the vaccinated patients, 61(87.14%) had received only one dose of either vaccine while 9(12.85%) patients had received both doses of the vaccine.

Axial scans of the thorax were obtained on a 6-slice CT scanner (Siemens Emotion). Following the scan, a CT severity score (CTSS) [6] was assigned depending on the extent of involvement of each lobe of the lungs (0-normal, 1:<5% involvement, 2: 5-25% involvement, 3:26-50% involvement, 4: 51-75% involvement, 5: >75% involvement) with a total score ranging from 0-25 for both lungs. Based on the CTSS the patients were grouped into three categories i.e., mild, moderate and severe for a score of  $\leq 7$ , 8-17 and  $\geq 18$  respectively [6].

## 2.1 : Statistical analysis:

The presentation of the categorical variables was done in the form of numbers and percentage (%). The quantitative data were presented as the mean $\pm$  SD and as median with 25th and 75th percentiles (interquartile range). The following statistical tests were applied for the results:

1. The comparison of the variables which were quantitative in nature and normally distributed was done using independent t test and non-normally distributed data was analyzed using Mann Whitney test.
2. The comparison of the variables which were qualitative in nature was done using Chi-Square test.

The data entry was done in Microsoft EXCEL spreadsheet and the final analysis was done with the use of Statistical Package for Social Sciences (SPSS) software, IBM manufacturer, Chicago, USA, version 21.0. For statistical significance, p value of less than 0.05 was considered statistically significant.

### 3. RESULTS

The demographics of the study subjects in both groups were similar in terms of mean age and gender distribution (Table 1). No significant difference in CTSS was found in patients with and without co-morbidities (p value=0.018). On comparing the number of patients with mild, moderate and severe disease based on the CTSS, we found a statistically significant difference between the two groups (Table 2). A greater percentage of the unvaccinated subjects (72.86%) had severe disease [Figure 1 and 2] compared to the vaccinated group (38.57%) whereas, a greater percentage of the vaccinated patients had mild to moderate disease (30 % and 31.43% respectively) [Figure 3 and 4]. Only 5.71% of the unvaccinated patients had mild disease. The mean CTSS of patients with at least one dose of vaccination was found to be significantly lower than that of patients who were unvaccinated i.e.,  $13.33 \pm 8.06$  and  $19.3 \pm 5.52$  respectively. Similar observations were made on comparing the median scores of both groups. We found a correlation between the CTSS and the age of the patients (Correlation coefficient =0.214, P value=0.011), with severe disease seen in patients in the older age groups (mean age  $53.64 \pm 11.87$  years). No correlation was found with gender of the patients (Table 3 and graph 1).

**Table 1:- Comparison of demographic characteristics between unvaccinated and vaccinated group.**

Demographic characteristics	Unvaccinated(n=70)	Vaccinated(n=70)	Total	P value
<b>Age(years)</b>				
Mean $\pm$ SD	$51.83 \pm 12.05$	$50.04 \pm 14$	$50.94 \pm 13.05$	
Median (25th-75th percentile)	51(43-60)	51(38.5-60)	51(43-60)	0.42*
Range	28-82	22-85	22-85	
<b>Gender</b>				
Female	24 (34.29%)	25 (35.71%)	49 (35%)	0.859‡
Male	46 (65.71%)	45 (64.29%)	91 (65%)	

\* Independent t test, ‡ Chi square test

**Table 2:-Comparison of CTSS between unvaccinated and vaccinated group.**

CTSS	Unvaccinated(n=70)	Vaccinated(n=70)	Total	P value
Mild	4 (5.71%)	21 (30%)	25 (17.86%)	
Moderate	15 (21.43%)	22 (31.43%)	37 (26.43%)	<.0001 <sup>‡</sup>
Severe	51 (72.86%)	27 (38.57%)	78 (55.71%)	
Mean ± SD	19.3 ± 5.52	13.33 ± 8.06	16.31 ± 7.5	
Median(25th-75th percentile)	21(17-23)	14.5(7-20)	18(12.75-23)	<.0001 <sup>†</sup>
Range	0-25	0-25	0-25	

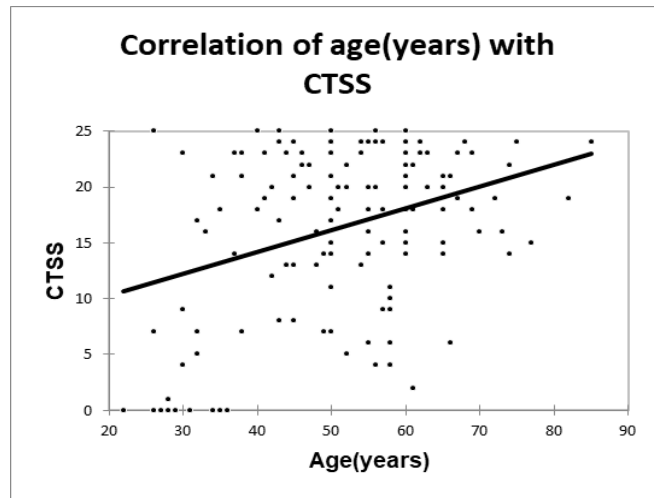
<sup>†</sup> Mann Whitney test, <sup>‡</sup> Chi square test

**Table 3:-Association of demographic characteristics with CTSS.**

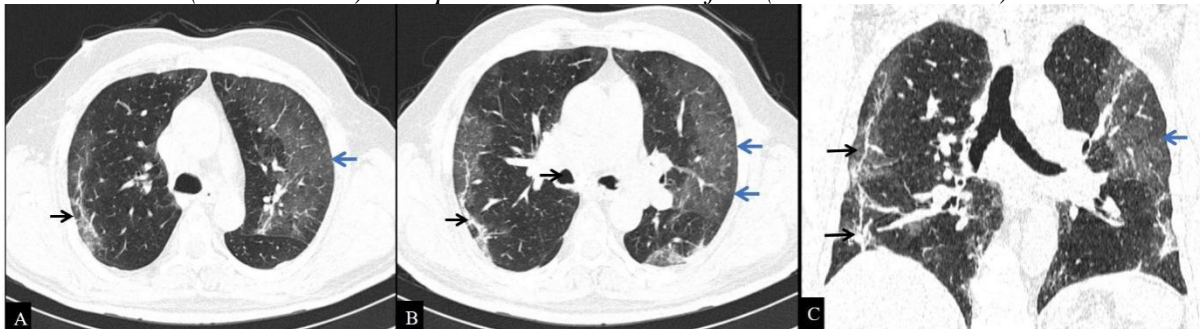
Demographic characteristics	Mild(n=25)	Moderate(n=37)	Severe(n=78)	Total	P value
<b>Gender</b>					
Female	12 (24.49%)	11 (22.45%)	26 (53.06%)	49 (100%)	0.301 <sup>†</sup>
Male	13 (14.29%)	26 (28.57%)	52 (57.14%)	91 (100%)	
<b>Age(years)</b>					
Mean ± SD	40.68 ± 13.8	52.16 ± 11.78	53.64 ± 11.87	50.94 ± 13.05	
Median(25th-75th percentile)	35(29-55)	50(44-58)	54(45.25-61)	51(43-60)	<.0001 <sup>§</sup>
Range	22-66	30-77	26-85	22-85	

<sup>†</sup> Chi square test, <sup>§</sup> ANOVA

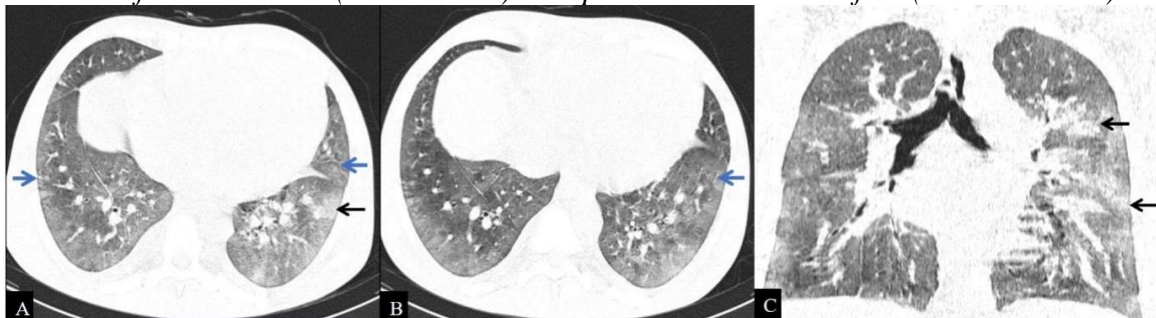
**Graph 1:-Correlation of age with CTS.**



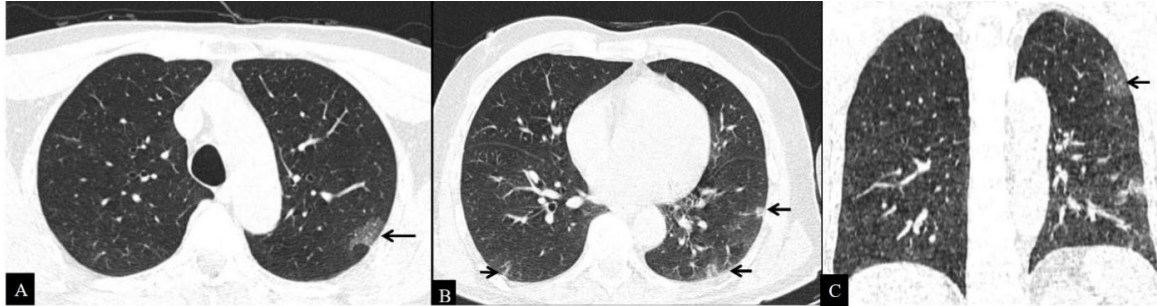
**Figure 1:** (A-C): Axial (A-B) and coronal (C) non-contrast CT scan sections in lung window of a 60-year-old unvaccinated male patient show multiple areas of ground glass attenuation in bilateral lungs with peripheral predilection (blue arrows) along with subpleural bands in the right lung (black arrow). The patient had a CTSS of 15 (moderate disease).



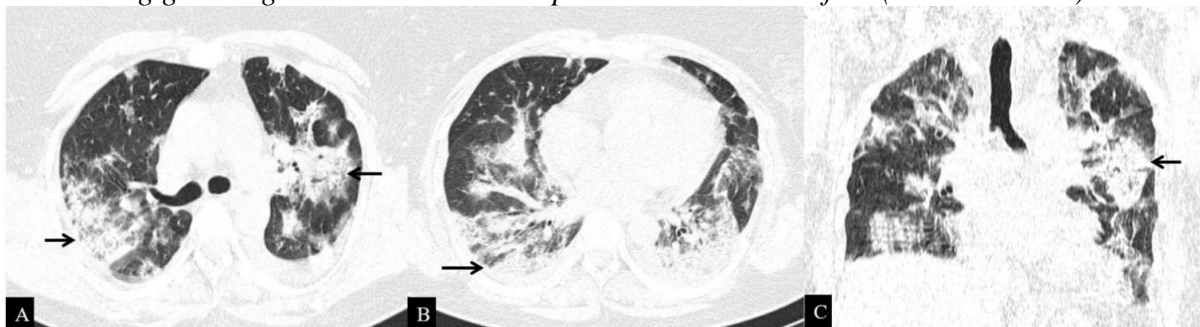
**Figure 2:** (A-C): Axial (A-B) and coronal (C) non-contrast CT scan images in lung window of a 56-year-old unvaccinated male show diffuse areas of ground glass attenuation with interlobular septal thickening in bilateral lungs predominantly in the lower lobes (blue arrows) along with few patchy areas of consolidation (black arrow). The patient had a CTSS of 25 (severe disease).



**Figure 3:** (A-C): Axial (A-B) and coronal (C) non-contrast-CT scan sections in lung window of a 66-year-old male who had received 1 dose of vaccine show multifocal patchy areas of ground glass attenuation showing peripheral and basal distribution (arrows). The patient had a CTSS of 6 (mild disease).



**Figure 4:** (A-C): Axial(A-B) and coronal (C) non-contrast CT scan sections in lung window of a 50-year-old vaccinated female show large multifocal areas of consolidation (arrow) with surrounding ground glass attenuation. The patient had a CTSS of 19 (severe disease).



#### 4. DISCUSSION

As described by numerous previous studies, the most common pattern of lung involvement seen in COVID-19 pneumonia is the presence of multifocal ground glass opacities in bilateral lungs showing posterior and basal predominance [7]. Other imaging findings include consolidation, crazy paving pattern, pulmonary vascular enlargement, halo sign, bronchial wall thickening and reverse halo sign. In late stages, features of fibrosis may be seen including subpleural parenchymal bands, architectural distortion and tractional bronchiectasis [7]. The pathological correlates for the predominant findings namely ground glass opacities and consolidation being capillary dilatation along with congestion, interstitial edema, and diffuse alveolar damage [8]. The article by Dr Lee and col-

leagues published in the June 2022 issue of Radiology discusses the imaging and clinical features of COVID 19 breakthrough infections [9]. In their cohort of 412 hospitalized patients with COVID-19, patients vaccinated for COVID-19 exhibited fewer findings of COVID-19 pneumonia at chest CT than did patients who were not vaccinated. Additionally, the need for ventilatory support and the frequency of intensive care unit admission were significantly lower in the vaccinated group than in the unvaccinated group.

The patients in our study had received either Covaxin or Covishield. Initially, a gap of 4 weeks was approved between the two doses of either vaccine. Presently, for Covishield, an interval of 12-16 weeks has been approved in India. A study conducted in India compared the antibody response following the first dose of Covaxin to that of Covishield and found that the responder rate and the rise in anti-spike antibody was significantly higher with Covishield as compared to Covaxin [10].

It has been found that the CT severity score can be used as a useful marker for predicting short term mortality in patients with COVID-19 pneumonia by providing an estimate of the actual anatomical damage to the lungs. The CTSS has also been found to correlate with the disease severity. The scores were found to be lower in patients with mild disease [11].

The study done by Gurumurthy et al used CT severity score as a potential imaging bio marker to evaluate the disease severity among vaccinated and unvaccinated patients of COVID pneumonia. It revealed reduced CT severity score in vaccinated patients and a positive protective effect of the vaccines among symptomatic patients [12].

In this study, we have assessed the effect of vaccination on the extent of lung involvement in patients with COVID-19 pneumonia using CT severity score as a measure of severity of lung disease. The patients were divided into those with mild, moderate and severe disease based on the scores and comparison was made between the vaccinated and unvaccinated study population.

Earlier studies have shown a reduction in the clinical severity and hospital admission rates in patients vaccinated against the virus [4,5]. An Indian study done by Atre et al, published in June 2022 also revealed lower mean CTSS in fully vaccinated cohort than in partially vaccinated and unvaccinated cohort. Also, the mean CTSS was found to be higher in presence of co – morbidities [13]. However, in the present study no significant difference in CTSS in patients with and without co-morbidities was found. This difference could be due to referral bias and the relatively low sample size in the present study.



In our study it was found that a greater percentage of vaccinated patients had mild disease reflected in the mean CTSS i.e., 30 % of vaccinated patients as compared to only 5.71% of unvaccinated patients. On the contrary, a higher percentage i.e., 72.86% of unvaccinated patients had severe disease i.e., patients had a CTSS of  $\geq 18$  indicating more extensive lung involvement. Since most i.e., 87.14% of the patients had received only one dose of either vaccine we conclude that even a single dose of vaccine can effectively reduce the severity of pulmonary involvement as assessed by the CTSS. This preliminary study emphasizes the importance of vaccination and the need for robust system of vaccination in order to maximize the benefits. One limitation of this study was that the presence of co-morbidities was not taken into account which might have influenced the disease severity.

## 5. CONCLUSIONS

On comparing the CTSS of patients with and without vaccination in our study, we found a significant reduction in the scores in the vaccinated group. The vaccine's efficacy could be validated objectively, thus, emphasizing the role of vaccination in our fight against the pandemic.

## REFERENCES

- [1] World Health Organization. **Weekly epidemiological update on COVID-19.**  
<https://www.who.int/publications/m/item/weekly-epidemiological-update-on-covid-19-19-october-2022>
- [2] Kumar VM, Pandi-Perumal SR, Trakht I, Thyagarajan SP. Strategy for COVID-19 vaccination in India: the country with the second highest population and number of cases. **npj Vaccines.** 2021 Apr 21;6(1):1-7.
- [3] Centers for Disease Control and Prevention. The possibility of COVID-19 after vaccination: breakthrough infections. <https://www.cdc.gov/coronavirus/2019->

[ncov/vaccines/effectiveness/why-measure-effectiveness/breakthrough-cases.html](#).

Published September 7, 2021. Accessed November 3, 2021.

- [4] Rana EA, Dutta P, Islam MS, Nizami TA, Das T, Chowdhury S, Das GB. Severity assessment of single dose Oxford–AstraZeneca vaccinated individuals infected with SARS CoV-2 in the Southeast Bangladesh. **medRxiv**. 2021 Jan 1.
- [5] Glampson B, Brittain J, Kaura A, Mulla A, Mercuri L, Brett S, Aylin P, Sandall T, Goodman I, Redhead J, Saravanakumar K. North West London Covid-19 Vaccination Programme: Real-world evidence for Vaccine uptake and effectiveness. **medRxiv**. 2021 Jan 1.
- [6] Francone M, Iafrate F, Masci GM, Coco S, Cilia F, Manganaro L, Panebianco V, Andreoli C, Colaiacomo MC, Zingaropoli MA, Ciardi MR. Chest CT score in COVID-19 patients: correlation with disease severity and short-term prognosis. **European radiology**. 2020 Dec;30(12):6808-17.
- [7] Kwee TC, Kwee RM. Chest CT in COVID-19: what the radiologist needs to know. **RadioGraphics**. 2020 Nov;40(7):1848-65.
- [8] Henkel M, Weikert T, Marston K, Schwab N, Sommer G, Haslbauer J, Franzeck F, Anastasopoulos C, Stieltjes B, Michel A, Bremerich J. Lethal COVID-19: Radiologic-Pathologic Correlation of the Lungs. **Radiology: Cardiothoracic Imaging**. 2020 Nov 19;2(6):e200406.
- [9] Lee JE, Hwang M, Kim YH, Chung MJ, Sim BH, Chae KJ, Yoo JY, Jeong YJ. Imaging and Clinical Features of COVID-19 Breakthrough Infections: A Multicenter Study. **Radiology**. 2022 Jun;303(3):682-92.
- [10] Singh AK, Phatak SR, Singh R, Bhattacharjee K, Singh NK, Gupta A, Sharma A. Antibody response after second-dose of ChAdOx1-nCOV (Covishield™®) and BBV-152 (Covaxin™®) among health care workers in India: final results of cross-sectional coronavirus vaccine-induced antibody titre (COVAT) study. **medRxiv**. 2021 Jan 1.
- [11] Kovács A, Palásti P, Veréb D, Bozsik B, Palkó A, Kincses ZT. The sensitivity and specificity of chest CT in the diagnosis of COVID-19. **European Radiology**. 2021 May;31(5):2819-24.

- [12] Gurumurthy B, Das SK, Shetty S, Veerabhadrapa RC, Kosinepalli SS, Dharamaraju SH. CT severity score: an imaging biomarker to estimate the severity of COVID-19 pneumonia in vaccinated and non-vaccinated population. **Egyptian Journal of Radiology and Nuclear Medicine**. 2022 Dec;53(1):1-8.
- [13] Atre AL, Atre A, Panchawagh S, Khamkar R, Chandorkar A, Patil S. Association between Chest CT Severity Scores and SARS-CoV-2 Vaccination among COVID-19 patients: A Cross-sectional Study from Pune, India. **Journal of Clinical & Diagnostic Research**. 2022 Jun 1;16(6).

This article is licensed under a Creative Commons Attribution 4.0 International License, which permits use, sharing, adaptation, distribution and reproduction in any medium or format, as long as you give appropriate credit to the original author(s) and the source, provide a link to the Creative Commons license, and indicate if changes were made. The images or other third-party material in this article are included in the article's Creative Commons license, unless indicated otherwise in a credit line to the material.

To view a copy of this license, visit <http://creativecommons.org/licenses/by/4.0/>